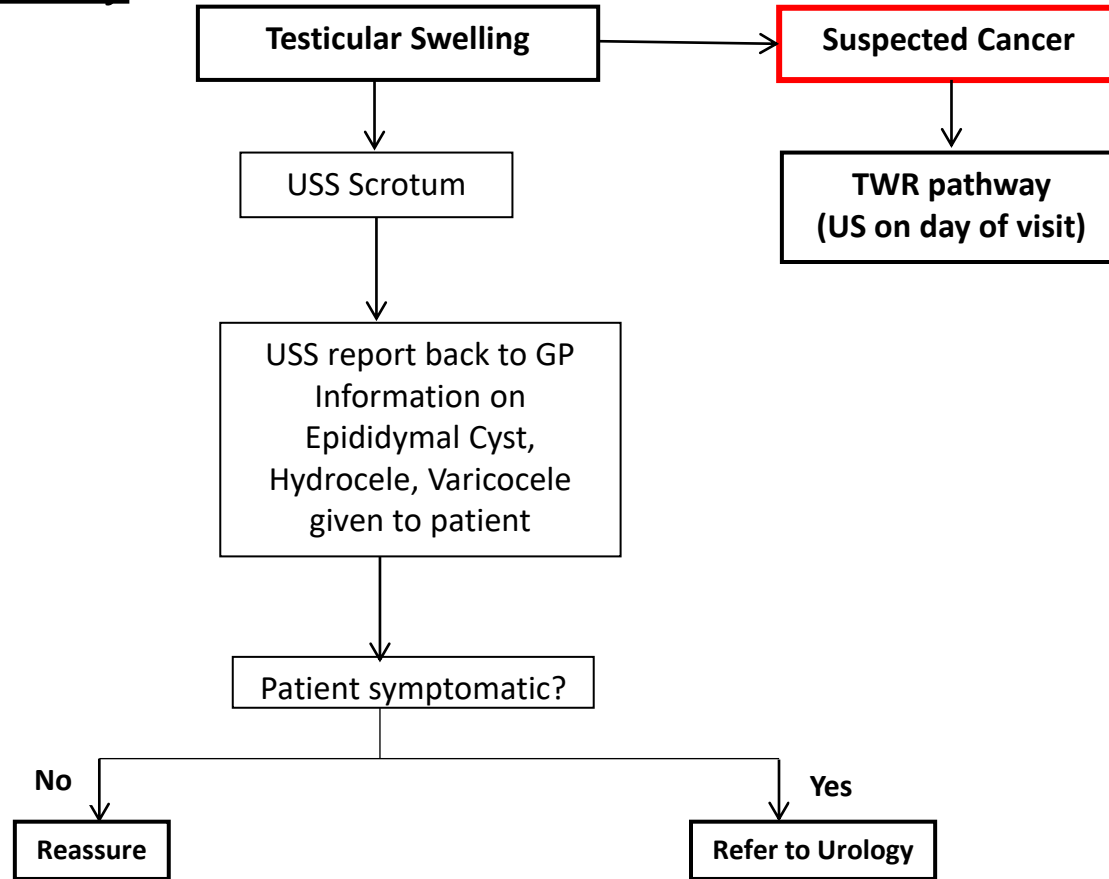


# SWL Testicular Pathway



[https://www.baus.org.uk/\\_userfiles/pages/files/Patients/Leaflets/Hydrocele.pdf](https://www.baus.org.uk/_userfiles/pages/files/Patients/Leaflets/Hydrocele.pdf)  
[https://www.baus.org.uk/\\_userfiles/pages/files/Patients/Leaflets/Varico%20emb.pdf](https://www.baus.org.uk/_userfiles/pages/files/Patients/Leaflets/Varico%20emb.pdf)  
[https://www.baus.org.uk/\\_userfiles/pages/files/Patients/Leaflets/Epididymal%20cyst.pdf](https://www.baus.org.uk/_userfiles/pages/files/Patients/Leaflets/Epididymal%20cyst.pdf)